



Amol University of Special
Modern Technologies

Caspian Journal of Veterinary Science

doi: 10.22034/cjvs.2024.210706

Journal homepage: <https://cjvs.ausmt.ac.ir/>

Prevalence of hemobartonellosis in domestic cats of Ahvaz city

Soroush Zibae^{1*}, Bahman Moslanejad², Seyede Misaq Jalali², Somaieh Bahrami³, Reza Avizah²

¹Faculty of Veterinary Medicine, Shahid Chamran University of Ahvaz, Ahvaz, Iran.

²Department of Clinical Sciences, Faculty of Veterinary Medicine, Shahid Chamran University of Ahvaz, Ahvaz, Iran.

³Department of Pathobiology, Faculty of Veterinary Medicine, Shahid Chamran University of Ahvaz, Ahvaz, Iran.

(*) Corresponding Author: zibae.soroush@gmail.com

Article Info	Abstract
Article history: Received: 11 July 2024 Accepted: 15 August 2024	<p>Hemobartonellosis is a condition found in cats characterized by symptoms of anemia. A cat with this infection is frequently tired and has a reduced appetite. Signs such as anemia, pale gums, fever, and occasionally an enlarged spleen may be observed. In certain instances, anemia may be mild, extremely severe, and result in the animal's death. The objective of this study was to examine how common hemobartonellosis is in pet cats. The task was completed in Ahvaz city. Research was conducted on 78 cat collars in Ahvaz city from 2016 to 2020, revealing cases of hemobartonellosis in both male (49) and female (29) cats. Initially, one milliliter of blood was collected from the cephalic vein of 78 domestic cats in Ahvaz city, followed by transferring each sample onto individual slides and staining them with Giemsa dye. The slides were examined with a light microscope to check for <i>Hemobartonella</i> contamination. The findings indicated a 5.13% infection rate, with only four out of 78 cats testing positive, including three males and one female. Furthermore, there were four cases of infection linked to the Mokotah breed within the country, while the Persian breed remained uninfected ($p < 0.05$). Samples that had been infected were older than two years ($p < 0.05$). Based on the findings, age and breed are important variables in the development of this disease in pet cats.</p>
Keywords: Ahvaz Domestic cats Hemobartonellosis <i>Mycoplasma</i> Prevalence	

© 2024 Published by Amol University of Special Modern Technologies Press.

This is an open-access article under the CC-BY 4.0 license. (<https://creativecommons.org/licenses/by/4.0/>)

Introduction

Hemotropic mycoplasmas in cats are parasites on red blood cells, consisting of three types: *Mycoplasma hemophilis*, *Candidatus Mycoplasma hominotum*, and *Candidatus Mycoplasma torisensis*. *M. hemophilis* is the most pathogenic of the three species mentioned (Atyabi *et al.*, 2009; Sykes, 2010; Vahedi *et al.*, 2013). These organisms, previously identified as *Hemobartonella felis*, are now recognized as *Mycoplasma* and are responsible for causing infectious anemia in cats (Turkan, 2015). These bacteria actually lack walls, the ability to be cultivated, and

polymorphism, and have a small genome (Akhtar Danesh *et al.*, 2011; Hemasri *et al.*, 2018). Hemoplasmas, also known as hemotropic mycoplasmas, lead to red blood cell infection and the development of hemobartonellosis in both domestic and wild cats, resulting in varying degrees of anemia with extravascular hemolysis (Hosseini Hoshjar, 2012).

The methods of spreading this illness are not fully understood, but it appears that the disease can be passed through insects like lice, fleas, ticks, and

mosquitoes, as well as by infected cat saliva, blood transfusions, contaminated surgical tools, and from mother to unborn child (Foley et al., 1998; Akhtar Danesh et al, 2011; Francisco et al., 2017).

Parasites become active in the blood within 2-17 days of infection and can remain active for a period of 3-8 weeks. Usually, they manifest in three ways: acute form (severe anemia symptoms), subacute form (no symptoms), and chronic form. The symptoms of anemia differ based on the severity of the condition, whether it is mild or severe. Symptoms can range from lethargy, fever, weakness, loss of appetite, periodic fevers, jaundice, pale gums, occasional enlarged spleen and jaundice, increased heart rate, neurological symptoms, eye problems, reproductive disorders, rapid breathing, and weight loss. Severe anemia can lead to extreme depression and possible death in the animal in certain situations. The only treatment for this disease once it is diagnosed is to prescribe antibiotics that work against *Mycoplasma* and then address the cat's anemia and dehydration. In cats with *M. hemophilis* infection, not all infected cats will develop anemia, but their immune system may be weakened in cases such as being infected with feline leukemia virus (FeLV) or feline immunodeficiency virus (FIV) (Foley et al., 1998; Vahedi et al., 2013; Lopez and Martinson, 2017). Consequently, there will be a development of severe anemia. Besides impacting red blood cells, this parasite also influences the spleen, bone marrow, and white blood cells. The most effective method for diagnosis is by extracting a blood sample and analyzing it using a microscope or molecular techniques like PCR (Kristi and Lively, 2011). The current research examined the occurrence of hemobartonellosis in domestic cats in Ahvaz city and its correlation with factors like age, gender, and breed.

Materials and Methods

This research involved analyzing the records of 78 cats (comprising 49 males and 29 females) in Ahvaz from 2016 to 2020 for hemobartonellosis at the clinical pathology and parasitology lab of the Faculty of Veterinary Medicine, Shahid Chamran University. Initially, one milliliter of blood was taken from the cephalic vein of 78 domestic cats in Ahvaz city, and then each blood sample was placed on individual slides and dyed with Giemsa. Ultimately, the slides that were prepared were examined using a light microscope to detect any presence of *Hemobartonella* contamination. The data was assessed using chi square test with consideration of age, gender, and race factors. Additionally, Spearman's correlation test was

employed to assess the connection between variables. All the analyses were carried out with the SPSS-16 program and were deemed to be statistically significant.

Results

Table 1 showed the frequency and percentage of occurrence of hemobartonellosis in domestic cats of Ahvaz city based on age, gender, and breed.

Table 1. Investigation of the frequency and percentage of occurrence of hemobartonellosis in domestic cats of Ahvaz city based on age, gender, and breed.

	Uncontaminated		Infected		Number	Variables
	Percentage	Abundance	Percentage	Abundance		
Age	100	43	-	-	43	Under 2 years
	58/88	31	42/11	4	35	Above 2 years
Sex	88/93	46	12/6	3	49	Male
	56/69	28	44/3	1	29	Female
Race	100	15	-	-	15	Persian
	66/93	59	34/6	4	63	domestic short hair

An analysis of cases spanning from 2016 to 2020 revealed that 5.13% of 78 cats were found to be infected (Fig. 1). There was no statistically significant difference observed in the infection rates between males (3 out of 49) and females (1 out of 29) ($p > 0.05$). Of the 78 cats in total, 15 were Persian cats with no infections, and 63 were domestic short haired cats (DSH) with four cases of contamination, showing a significant difference ($p < 0.05$). Furthermore, out of the 78 cats examined, 43 younger than two years showed no contamination, while 35 older than two years were observed with contamination, indicating all four contamination cases were in the older age group, implying a significant difference ($p < 0.05$).

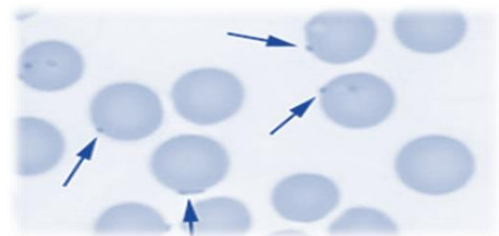


Fig. 1. A view of pollution hemobartonellosis observed in domestic cats.

Discussion

The aim of this research was to examine how common hemobartonellosis is among 78 domestic cats

in Ahvaz city. Over the course of four years (2016-2020), a total of four out of 78 cats were discovered to have contracted hemobartonellosis disease, accounting for 5.13%. Hemoplasmas, also known as hemotropic mycoplasmas or *Hemobartonella*, infect the feline family, consisting of domestic and wild cats. When the red blood cell becomes infected with the *Hemoplasma* parasite, its lifespan in the bloodstream is short-lived. This parasite is able to harm the red blood cell membrane, leading to the cell breaking open. The body can also eliminate damaged blood cells, leading to a decrease in the number of red blood cells and causing anemia (Atyabi *et al.*, 2009; Kristi and Lively, 2011).

America, Australia, and Thailand have reported the prevalence of this disease as 19.4%, 15.3%, and 16.3%, respectively (Ranjbar Bahadri *et al.*, 2014). Akhtar Danesh *et al.* (2011) found that *M. hemophilis* was present in 31% of the cats studied, and its presence was strongly associated with anemia in the population. This disease was revealed by researchers to be among the most prevalent parasitic diseases in cats in Iran. Furthermore, Ranjbar Bahadri *et al.* (2014) research on 120 cat collars in Tehran found that 11.67% were contaminated with *Hemobartonella*. Atyabi *et al.* (2009) revealed that the occurrence of hemobartonellosis in infected cats falls between 14% and 30% with a 95% confidence interval. Furthermore, male cats were 20 times more likely to get this disease compared to female cats according to a study. This study also showed infection rates of 6.12% in males and 3.44% in females. In a study conducted by Borji *et al.* (2011) in Mashhad, the prevalence of *Hemobartonella* was found to be 1.9% in 54 cats. Their research findings indicated that there is no correlation between the contamination level and the gender of the cats examined. Contamination was observed in the age category over 1.5 years in the research conducted by Oskouizadeh *et al.* in 2008. Grindem *et al.* (1990) mentioned that for this disease to occur, factors like being under three years old, having anemia, and having an abscess at the bite location were influential. They also highlighted the importance of factors like gender, breed, and number of cats in preventing contamination.

Cats excel at concealing signs of sickness, particularly anemia, which means symptoms may go unnoticed in a cat until the anemia reaches a severe stage. Cats with anemia are typically sad and lacking in energy, with a possible decrease in their appetite. Their oral and ocular membranes may seem lighter than usual, or they may develop a yellow hue in cases of jaundice caused by increased red blood cell

breakdown. Cats who are severely impacted may struggle with their breathing and experience shortness of breath, even with slight exercise. Hence, timely detection and therapy of feline infectious anemia are crucial for increasing the possibility of full recovery (Kristi and Lively, 2011; BSVH, 2021).

If there is suspicion of a hemotropic *Mycoplasma* infection, starting treatment promptly can increase the likelihood of a complete recovery. Tetracycline is effective against all *Mycoplasma* infections. Administering the doxycycline derivative to cats is simple because it can be given orally in suspension form. Exercise caution when administering tablets to cats as they may get lodged in the esophagus, leading to irritation and ulcers. If oral tablets are recommended, they must be taken with a few milliliters of water to avoid them sticking to the esophagus and causing irritation. Quinolone antibiotics like enrofloxacin have also been shown to be efficient in fighting hemotropic mycoplasmas. Three weeks of treatment are necessary to effectively control the organism. However, it may be necessary to administer antibiotics for an extended duration (up to eight weeks) in order to maximize the chances of fully clearing the infection in the cat. Total elimination of the organism is typically not required unless the cat is immunocompromised, or the spleen is or is expected to be affected. Nevertheless, eradicating *Mycoplasma* is just one aspect of the treatment. The destruction of red blood cells by the host's immune system needs to be prevented. Prednisolone or other steroids are commonly utilized to inhibit this aspect of the immune system in order to prevent rapid elimination of red blood cells. Severely ill cats will probably require blood transfusions in order to repair the harm done by the infection. Cats typically react positively and promptly to therapy. Carrier cats cannot be considered fully treated until their flea infestation is under control (BSVH, 2021). Furthermore, in cases of severe anemia in cats, hospitalization may be necessary for immediate care like blood transfusions, IV fluids, or nutritional assistance (Kristi and Lively, 2011).

Based on the findings of this study, age and breed play a significant role in the development of hemobartonellosis in pet cats. Hence, it is important to conduct regular blood tests to monitor red blood cell levels in cats two years and older, especially domestic short-haired breeds. In addition, it is essential to maintain strict control over external parasites for every cat.

Acknowledgements

This research has been supported by Shahid Chamran University of Ahvaz, Ahvaz, Iran.

Conflict of Interest

All authors declare that they have no conflicts of interest.

References

- Akhtar Danesh, B; Hosseini Hoshidar, S; Moini, TG and Hemti, Z** (2011). Molecular detection of *Mycoplasma haemophilis* infection in the population of stray cats in Kerman. *J. Vet. Lab. Res.*, 4: 87.
- Atyabi, N; Zahrai Salehi, T; Fazi Saeedi, F and Naderinejad, F** (1388). Molecular study of infection caused by hemotropic mycoplasmas (*hemobartonella*) in Tehran cats and its prevalence. The first national congress of veterinary laboratory sciences, Wednesday, December 11, organization of the veterinary system of the Islamic Republic of Iran.
- Bishops Stortford Veterinary Hospital (BSVH)** (2021). Feline Infectious Anemia (FIA). Retrieved from <https://www.stortvet.com>
- Borji, H; Razmi, G; Ahmadi, A; Karami, H; Yaghfoori, S and Abedi, V** (2011). A survey on endoparasites and ectoparasites of stray cats from Mashhad (Iran). *J. Parasit. Dis.*, 35: 202-206.
- Foley, JE; Harrus, S; Poland, A; Chomel, B and Pederson, NC** (1998). Molecular, clinical, and pathological comparison of two distinct strains of *Hemobartonella felis* in domestic cats. *Am. J. Vet. Res.*, 59: 1581-1588.
- Francisco, S; Walker, R; Sepulveda, M; Bittencourt, P; Acosta-Jamett, G and Müller, A** (2017). Occurrence of canine hemitropic mycoplasmas in domestic dogs from urban and rural areas of the Valdivia Province, southern Chile. *Comp. Immunol. Microbiol. Infect. Dis.*, 50: 70-77.
- Grindem, CB; Corbett, WT and Tomkins, MT** (1990). Risk factors for *Haemobartonella felis* infection in cats. *J. Am. Vet. Med. Assoc.*, 196: 96-99.
- Hemasri, S; Okene, IAA and Goni, MD** (2018). Feline hemotropic mycoplasmosis concurrent with bacterial cystitis in a domestic shorthair cat. *J. Adv. Vet. Anim. Res.*, 5: 490.
- Hosseini Hoshidar, Samira** (2012). Molecular detection of hemotropic *Mycoplasma* contamination in the population of stray cats in Kerman city. Veterinary Thesis, Faculty of Veterinary Medicine, Shahid Bahonar University of Kerman, Kerman, Iran.
- Kristi, S and Lively, DVM** (2011). Hemobartonellosis in cats. Retrieved from www.saintfrancis.org.
- Lopez, A and Martinson, SA** (2017). Respiratory system, mediastinum and pleurae. in J. F. Zachary (Ed.), *Pathologic basis of veterinary disease*. St. Louis, Mo.: Elsevier. PP: 471-560.
- Oskouizadeh, K; Zahraei Salehi, T; Aldavood, SJ; Majlesi, B; Ghaffari, H; Ashrafi Tamami, I and Aliari, A** (2008). Study in prevalence of *Bartonella henselae* infection in domestic cats from Tehran. *J. Vet. Res.*, 63: 183-189.
- Ranjbar Bahadri, S; Noshirvani, K and Shirani, D** (2014). Investigating the occurrence of hemobartonellosis in domestic cats in Tehran. *J. Vet. Res.*, 7: 23-28.
- Sykes, JE** (2010). Feline hemotropic mycoplasmas. *J. Vet. Emerg. Crit. Care*, 20: 62-69.
- Turkan, Sam** (2015). Comparative study of the treatment of parasitic disease (*Mycoplasma hemophilis*) by homeopathic method with common medicinal method in infected cats. The first national conference on common diseases between humans and animals, March 4, 2016, Isfahan Veterinary System Organization, Isfahan.
- Vahedi, SM; Balurchian, M; Shokoofeh Abul Qasimpour, S; Mazhari Nejadfard, R and Akbarin, H** (2013). Distribution and phylogenetic analysis of cat hemotropic mycoplasmas based on gene s rna16. *J. Vet. Res.*, 69: 213-217.